

**Impact
Factor
3.025**

ISSN 2349-638x

Refereed And Indexed Journal

**AAYUSHI
INTERNATIONAL
INTERDISCIPLINARY
RESEARCH JOURNAL
(AIIRJ)**

Monthly Publish Journal

VOL-IV

ISSUE-VI

JUN

2017

Address

• Vikram Nagar, Boudhi Chouk, Latur.
• Tq. Latur, Dis. Latur 413512 (MS.)
• (+91) 9922455749, (+91) 9158387437

Email

• aiirjpramod@gmail.com
• aayushijournal@gmail.com

Website

• www.aiirjournal.com

CHIEF EDITOR – PRAMOD PRAKASHRAO TANDALE

**“The Role of Shata Dhauta Ghrita Pichu in the Management of Pittaj Yoni Vyapad
W.S.R. to Cervical Erosion”: A Case Study**

Dr. Pallavi Ashok Chandanshiv

Affiliation:- M.S. Prasuti Tantra Stree Roga,
Assistant Professor at, CSMSS Ayurved College,
Auragabad, Maharashtra, India.
Email- drpallavichandanshiv@gmail.com

Abstract:-

Pittaj Yoni Vyapad is a common disorder. Excessive vaginal discharge, foul smell and burning sensation (Daha) are the most common signs and symptoms of the Pittaj Yoni Vyapad may be due Pitta dusti. In Ayurveda, Acharya Charka and Sushruta have explained 20 Yoni Vyapad. Out of that pittaj Yoni Vyapad is common disorder in women. The principle of treatment of Ayurveda is comparable to that of modern system of medicine in which cryosurgery and diathermy are used to destruct the columnar epithelium and facilitate the growth of new healthy stratified squamous epithelium. But because of various side effects like excessive mucous discharge per vagina for a long time, sometimes cervical stenosis, accidental burns, bleeding and recurrence of the disease may happen.

*Hence the Ayurvedic management seems to be more practical, effective, not costly and non-surgical and have negligible side effects. Due to serious consequences of the disease it becomes necessary to pay immediate attention towards this most troublesome disease of female. In chronic stage it can shows malignant changes so this case study was carried out in OPD of Prasuti Tantra Stree Roga Department, and the treatment drug i.e. **Shata Dhauta Ghrita Pichu** was taken. This drug has shown marked improvement in relieving all the symptoms of **Pittaj Yoni Vyapad** and was seen more effective in decreasing the vaginal discharge.*

Keyword: Cervix, **Shata Dhauta Ghrita**, Benign, **Pittaj Yoni Vyapad**.

Introduction

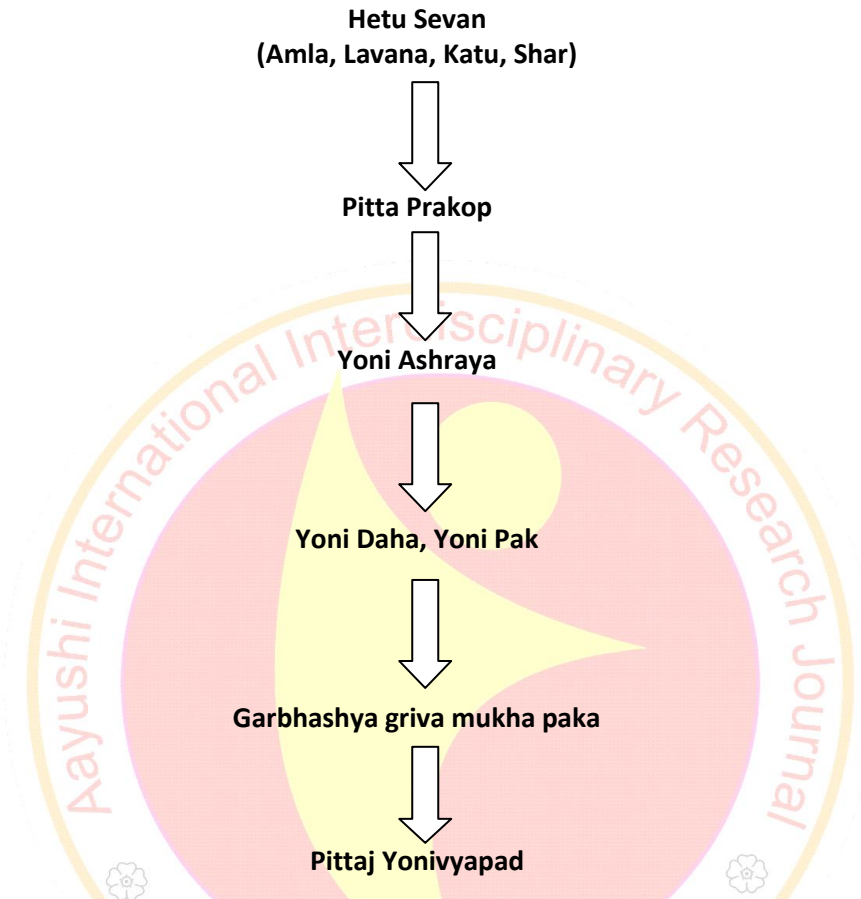
In Ayurveda, Acharya Charka and Sushruta explained 20 Yoni vyapad. Yoni vyapad is one of the factors of infertility (vandyatva).In Yoni vypad, Tryvarta Yoni, anatomy and their function are explained. Tryvarta Yoni means yoni is made up of 3 avarta-

1. Pratham Avarta- It starts from external opening of vagina up to the internal opening of vagina.
2. Dwitiya Avarta- It starts from internal opening of vagina up to the external OS of cervix.
3. Trutiya Avarta- It starts from the external OS of cervix up to whole Uterus, fallopian tube, fimbriae, ovary. Many Acharya explained Yoni vyapad, there are mainly 4 causes of 20 Yoni vyapad – Ref- Cha.Chi. 30-7/8.
 - A. Stree ne kelela mithya ahar vihar.
 - B. Dusta raja artav.
 - C. Sukra shonita sanyogane matrudwara allele Bja dosha.
 - D. Durdayva

Pittaj Yonivyapad :

व्यापत्कटूमूललवणक्षाराद्यैः पित्तजा भवेत्
दाहपाकज्वरोष्णार्ता नीलपीतासितार्तवा || च.चि.३०/११

Symptoms of cervical erosion i.e. discharge and erosion (like in pittaj Yoni vyapad) and the treatment mentioned in the Ayurvedic texts. Nidana sevan vitiates the vata (apana vayu). Pitta-vaigunya is present in the artavaha strotas, so here the vitiated vata get mixed with pittaja dosha and rakta dhatu and in this way the dosha dushya sammurchana is completed.



Adhithana of disease is the Garbhashaya griva mukha i.e. cervix (Astanga Sangraha Uttartantra 38/59 indu tika), so in the stage of vyakta avashtha, Garbhashya griva mukha paka is formed here which is the cardinal symptom of Pittaja yoni vyapad. So the Ayurvedic treatment having the properties of lekhana, sodhana⁵, ropana, stambhana, pittaghna⁶ can effectively cure this disease.

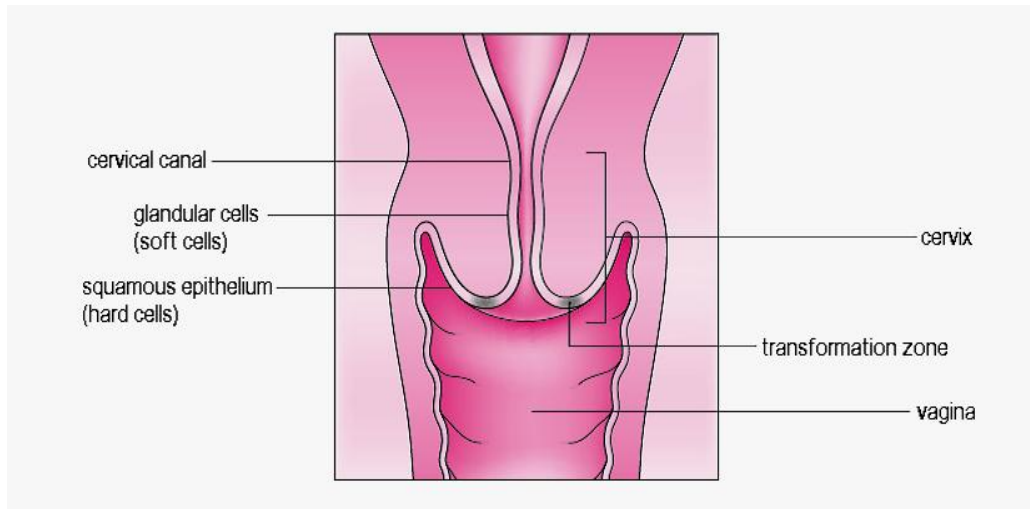
All the Acharya said on the Bahirparimarjan Chikitsa having vata pitta nashak properties cure the disease. So in the present case study pichu soaked in the **Shata Dhauta Ghrita** (Charaka Chikitsa 30/73-76) was prepared according to text mentioned in Sharangdhara Samhita and applied in the vagina and left inside for about 4-6 hours .

Pittaj Yoni vyapad, which is correlated with cervical erosion in modern. Cervical ectropion (also known as cervical erosion and ectopy) is a common condition caused when cells from inside the cervical canal, known as glandular cells (soft cells), are present on the outside surface of the cervix (neck of the womb).

The area where the soft cells meet the squamous epithelial cells (hard cells), which are those found on the outer surface of the cervix, is called the transformation zone. If a woman has cervical

ectropion, it can be seen by the nurse during a cervical screening test (smear test) and the area appears red (because soft cells are red).

Cervical ectropion can be caused by hormonal changes, pregnancy and being on the pill. It is **not** linked to the development of cervical cancer or any other condition that causes cancer.



For the majority of women, cervical ectropion does not cause any problems and it usually goes away by itself without needing any treatment.

However, as soft cells bleed more easily and can produce more mucus than hard cells, cervical ectropion may cause discharge, or bleeding/pain during or after sex. It can also sometimes cause pain during or after cervical screening. If any of these symptoms are causing problems for you, you may wish to look into treatment options. A member of the colposcopy team or your GP can provide you with more help on this and refer you for treatment, if necessary. If you choose to have treatment, it is usually given at a colposcopy clinic and will be done using heat/cautery, which hardens the soft cells to stop them from bleeding.

The 2 different treatment options are listed below:

- Silver nitrate to cauterise/burn off the soft cells (this should not be painful, however you may experience some mild discomfort).
- Cold coagulation which uses heat to cauterise/burn off the soft cells (you will be given a local anaesthetic to numb the area).

Both treatments can result in some bleeding or discharge, as well as some 'period-like' pain. This could last for around a week (1st method) or two to four weeks (2nd method) after the treatment. Tampons and penetrative intercourse should be avoided until you are fully healed, usually one week (1st method) or up to four weeks (2nd method).

Aim:-

“The Role Of Shata Dhauta Ghrita Pichu In The Management Of Pittaj Yoni Vyapad w.s.r. to Cervical Erosion”: A Case Study

Objectives:-

1. To study detail of **Pittaj Yoni Vyapad** .
2. To study symptomatic relief of **Pittaj Yoni Vyapad** by **Shata Dhauta Ghrita Pichu** therapy.

Type Of Study:-A Single case study.

Material And Method:-

Case Report

A 34 year old lady came in Feb 2017 in the OPD Prasuti Tantra- Stree Roga with complaints of excessive watery vaginal discharge from one year, burning at vagina, lower abdominal pain and pains all the upper and lower extremities.

On examination

A febrile
BP- 120/80
P- 76/min

Systemic examination

RS- clear
CVS and CNS- N
P/A- Lower abdomen tender.

On per speculum examination, it was found that vagina was very red, thick white discharge present, and oozing of blood on rubbing with gauze piece was present.

On per vaginal examination, it was found that uterus was anti-verted, antiflex and normal in size, cervix was down words forwards on touch and both the fornixes having slight tenderness. In the first visit the case was diagnosed as case of Pittaj Yoni Vyapad and few investigations were carried out and the reports were as follows

Blood investigations

- Hb-12.5gm%, TLC-9,700th/ul, ESR-11mm/hr, Neutrophill-64%, Lymphocytes-32%, Eosinophil-01%, Monocytes-02%, Basophil-01%, RBS- 80mg/dl; HIV, HBsAg, VDR-negative.
- Ultrasonography for uterus and adnexae - Normal study
Urine for routine and microscopy - Normal
Pap's Smear report - Mild inflammatory

Drug

Shata Dhauta Ghrita

Preparation of Shata Dhauta Ghrita

Reference: Charaka Samhita

Introduction

Shata Dhauta Ghrita is Ayurvedic preparation, usually recommended for treatment skin conditions. Ayurvedic medicine for damaged skin as ghrith penetrates and nourishes all seven layers of tissue.

Ingredients and Method of Preparation

- Pure Go Ghrith
This Ayurvedic ghrith was prepared by washing for 100 times purified ghee with water in copper plate.



Therapeutic Uses

- This Ayurvedic ghrith benefits by rejuvenating dermal tissue, supporting healing of skin.
- It can pacifies pain caused due to skin irritation.
- Effective in lessening the inflammation.
- It moisturizes the skin and act as an astringent.
- Excellent in reduction of skin problems like sunburn, rosacea, eczema, acne etc.

Contraindications/Side Effects

Till now no side effects has been reported.

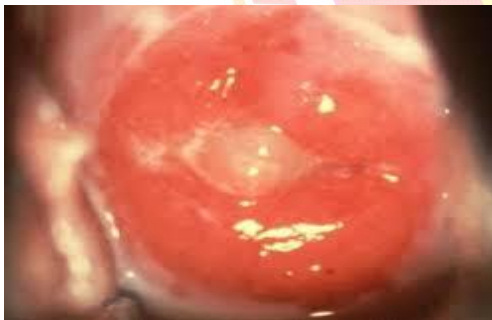Procedure of Ghrita Application:

Procedure of **Shato Dhauta Ghrita Pichu** application after taking written informed consent application of drug was done. Patient was called for **Shato Dhauta Ghrita Pichu** application after clearance of menstrual flow. Patient was kept in lithotomy position and preparation of part was done with Savlon solution. The cervix was exposed with Cusco’s speculum and cleaned properly. **Shato Dhauta Ghrita Pichu** was soaked with a gauze piece and kept in contact with the cervix. The ghrith was applied over the cervix and a pichu (piece of cotton wrapped with gauze and tie with thread) soaked with ghrith was kept inside the vagina for 4 to 6 hours. It was kept close to the cervix in such a way that some length of thread remained outside of the vagina. Patient was explained well to remove the pichu by holding this thread. The entire procedure was done for fourteen days for two consecutive cycles. After completion of the treatment patient was called weekly interval to see the symptomatic relief.

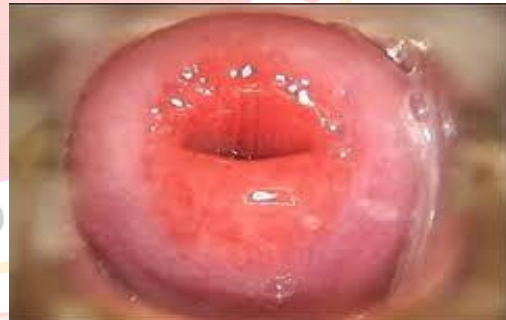Don’t: Sexual intercourse during the period of treatment.

Effect of Treatment Before treatment, after treatment Cervix of patient during Cusco’s speculum examination.

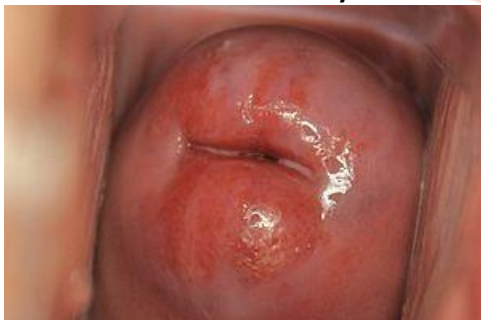Before treatment (1st visit)



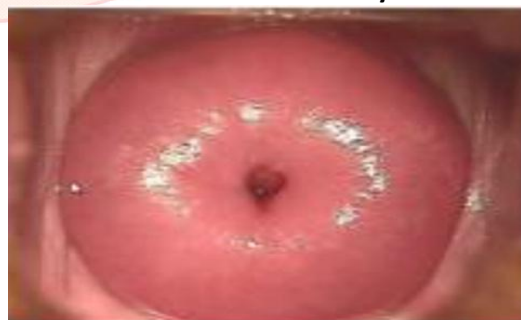2nd visit after 15 days:



3rd visit after 30 days:



4th visit after 45 days:



Result

The present drug gave the relief to the symptoms mainly vaginal discharge and daha after first menstrual cycle treatment. Gradually the eroded area also minimizes. The oozing of blood from eroded area after rubbing with gauze piece was also minimized. Maximum improvement was noticed in the vaginal discharge. It was completely abolished.

Discussion

Cervical erosion is found in the fertile age group i.e. 20- 35years, because of the repeated deliveries; there is local trauma in the Cervix, which may produce erosion. Due to hyperplasia of cervical glands various symptoms like vaginal discharge, contact bleeding, back pain, pelvic discomfort etc. produce which are disturbing elements in the daily life style of the woman. Vaginal discharge was disappeared earlier in this case.

The use of Shata Dhauta Ghrita Pichu probably prevents the congestion, thus prevented regeneration of superficial columnar cell. Most of the drug present in Shata Dhauta Ghrita Pichu is having anti- inflammatory, anti-septic and Pittashamak activities which prevent the eroded area from infection and may help in decrease the vaginal secretion. Anti-inflammatory effect of Shata Dhauta Ghrita Pichu may help to minimize the prostaglandin secretion² and hence the lower abdominal pain was cured in this case. Describing the effectiveness of this ghrith Acharya Charka mentions that with the use of this ghrith the darun yoni will be cured in only seven day or one week⁷. By virtue of shukshama⁸ and vyavayi⁸ properties the drug is easily absorbed through the epithelium and mucosa. Snigdha guna⁹ of ghrith helps in correction of pittavaigunya of artavavaha strotas.

Conclusion

Hence in this case we can conclude that Bahirparimarjan chikitsa in the form of Shata Dhauta Ghrita Pichu is highly effective in disintegration of pathogenesis of Garbhashya grivagath mukha paka (cervical erosion). No adverse effect or complications is produced with the use of this treatment. This treatment is safe economic, non-surgical, very effective and can be used for treatment of cervical erosion.

References

1. Dutta DC. Text book of gynecology including contraception; Benign lesion of cervix; Chapter 18; Fifth Edition: Kolkata; New Central Book Agency (P) Ltd. 2008, Revised Reprint; 2009. p.257
2. Dutta DC. Text book of gynecology including contraception; Benign lesion of cervix; Chapter 18; Fifth Edition: Kolkata; New Central Book Agency (P) Ltd. 2008, Revised Reprint; 2009. p.257
3. Tiwari Premvati. Ayurvedia Prasutitantra Avam Striroga, Vol.II; Yonivyapad; Chapter 1; Second Edition. Chaukamba Orientalia Varanasi;2000, Reprint; 2005. p. 41
4. Charaka, Charaka Samhita, Chikitsa Sthan 30/27, Vol.2 Commented By Sastri Kashinath And Chaturvedi Gorakhanath, Published By Chaukhambha Bharti Academy, Varanasi, Reprint Year; 2003. p. 844
5. Susruta.Sushruta Samhita, Uttar tantra 38/28, Vol.2 Shastri Ambikadutta, Published Chaukhambha Sanskrit Sansthan Varanasi, Reprint; 2005. p. 163
6. Charaka, Charaka Samhita, Chikitsa Sthan 30/109, Vol.2 Commented By Sastri Kashinath And Chaturvedi Gorakhanath, Published By Chaukhambha Bharti Academy, Varanasi, Reprint Year; 2003. p. 857 PMID:14702957
7. Charaka, Charaka Samhita, Chikitsa Sthan 30/76, Vol.2 Commented By Sastri Kashinath And Chaturvedi Gorakhanath, Published By Chaukhambha Bharti Academy, Varanasi, Reprint Year; 2003. p. 851 PMID:14521221
8. Charaka, Charaka Samhita, Sutra Sthan 27/286, Vol.1 Commented By Sastri Kashinath And Chaturvedi Gorakhanath, Published By Chaukhambha Bharti Academy, Varanasi, Reprint Year; 2003. p. 556
9. Sharma PV. Dravyagunavigyana, Vol.2, Chaukhambha Bharti Academy, Varanasi.Reprint; 2005. p. 221